

TICK ID CHART



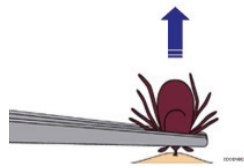
www.dupagehealth.org/ftb

 [fightthebitedupage](https://www.facebook.com/fightthebitedupage)

 [@fight_the_bite](https://twitter.com/fight_the_bite)

**ABATEMENT
 PARTNER LOGO**









TICK REMOVAL



- Do not burn or use any substance on tick.
- Do not grasp, squeeze or twist the body of tick.
- Grasp tick close to skin with tweezers.
- Pull tick straight out.
- Use antiseptic on skin afterward.
- Disinfect hands thoroughly

Always see a physician for possible diagnosis, testing and treatment, especially if tick parts remain after removal.

TICK IDENTIFICATION

NAME	MAGNIFIED	ACTUAL SIZE
<i>Ixodes scapularis</i> (deer tick, blacklegged tick) Found: Northeast, Upper Midwest	 <p>Nymph Adult Male Adult Female</p>	 <p>Larvae Nymph Adult</p>
<i>Amblyomma americanum</i> (lone star tick) Found: Eastern U.S.	 <p>Nymph Adult Male Adult Female</p>	 <p>Larvae Nymph Adult</p>
<i>Dermacentor variabilis</i> (dog tick) Found: All U.S.	 <p>Adult Male Adult Female</p>	 <p>Larvae Nymph Adult</p>
<i>Ixodes pacificus</i> (blacklegged tick) Found: Far West	 <p>Larvae Nymph Adult Male Adult Female</p>	 <p>Larvae Nymph Adult</p>
	Transmits: Lyme, babesiosis, anaplasmosis, Powassan encephalitis, tick paralysis, tularemia, Bartonella	
	Transmits: human monocytic ehrlichiosis, STARI, tularemia, tick paralysis, Rocky Mountain spotted fever	
	Transmits: Rocky Mountain spotted fever, tularemia, human monocytic ehrlichiosis	
	Transmits: Lyme, babesiosis, anaplasmosis, Bartonella	